

Echocardiography in The Intensive Care Unit

Cases presentation

BY

Dr. Fathi El-Allus, Echocardiography
subspecialty fellow

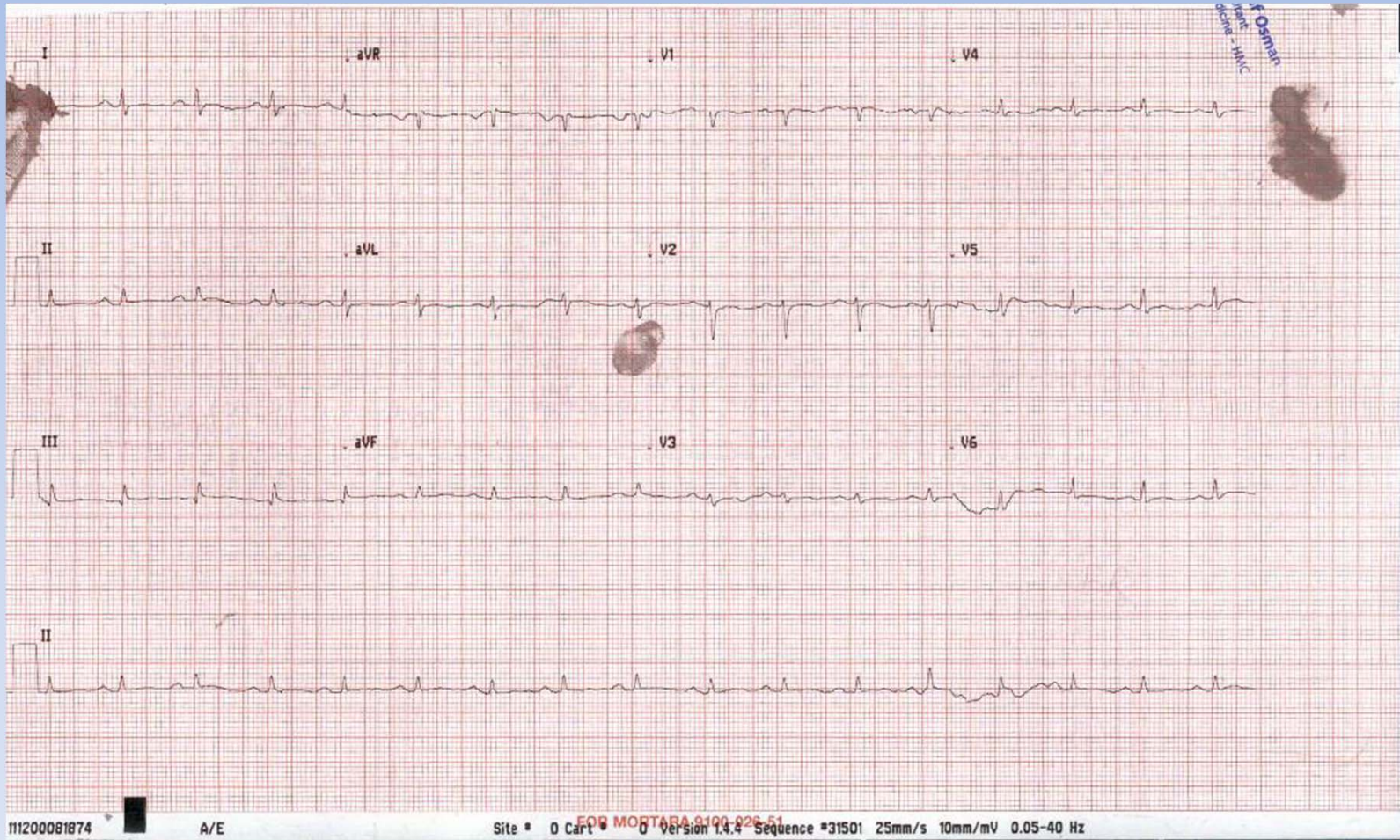
09-02-2019

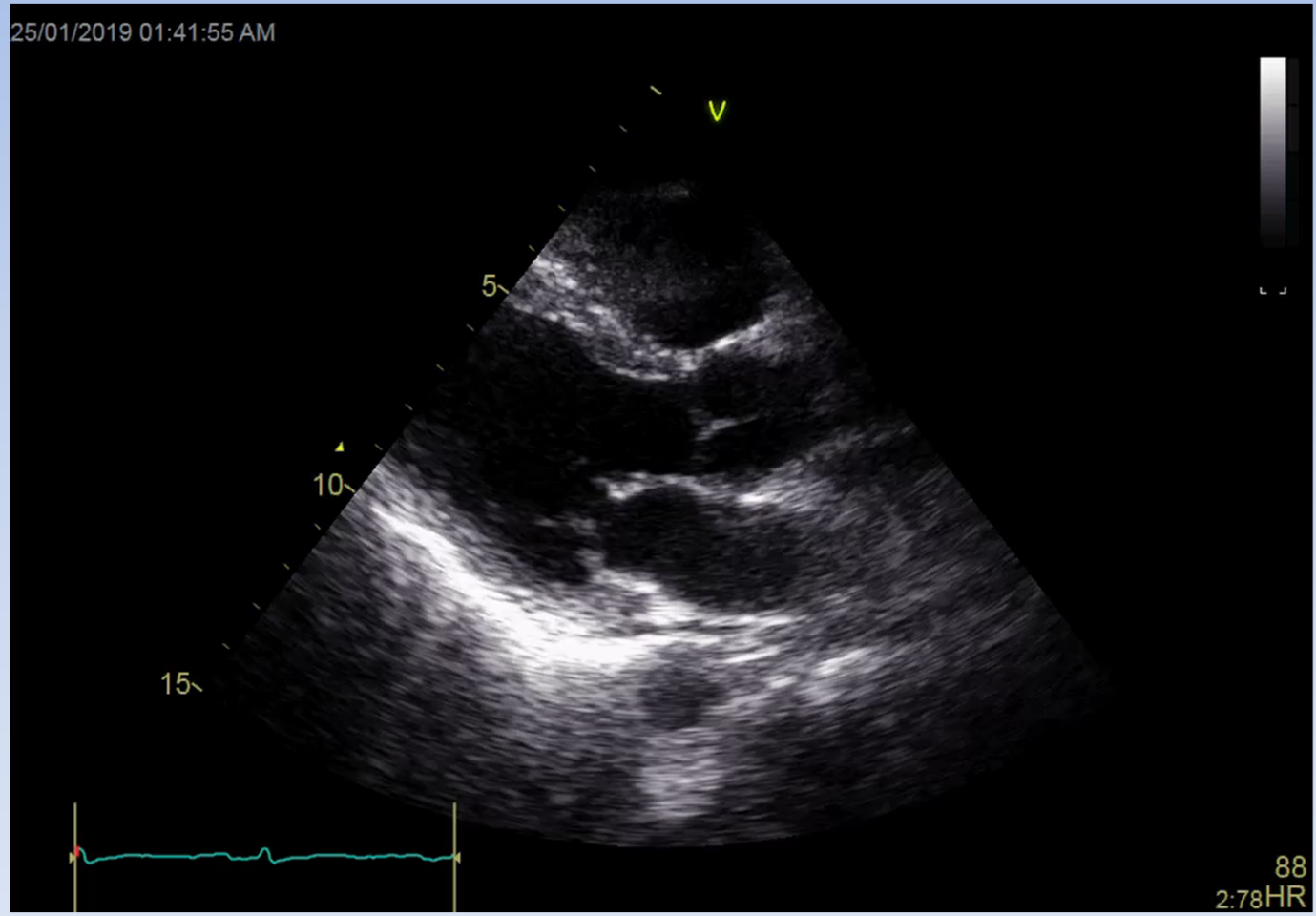
Disclosure

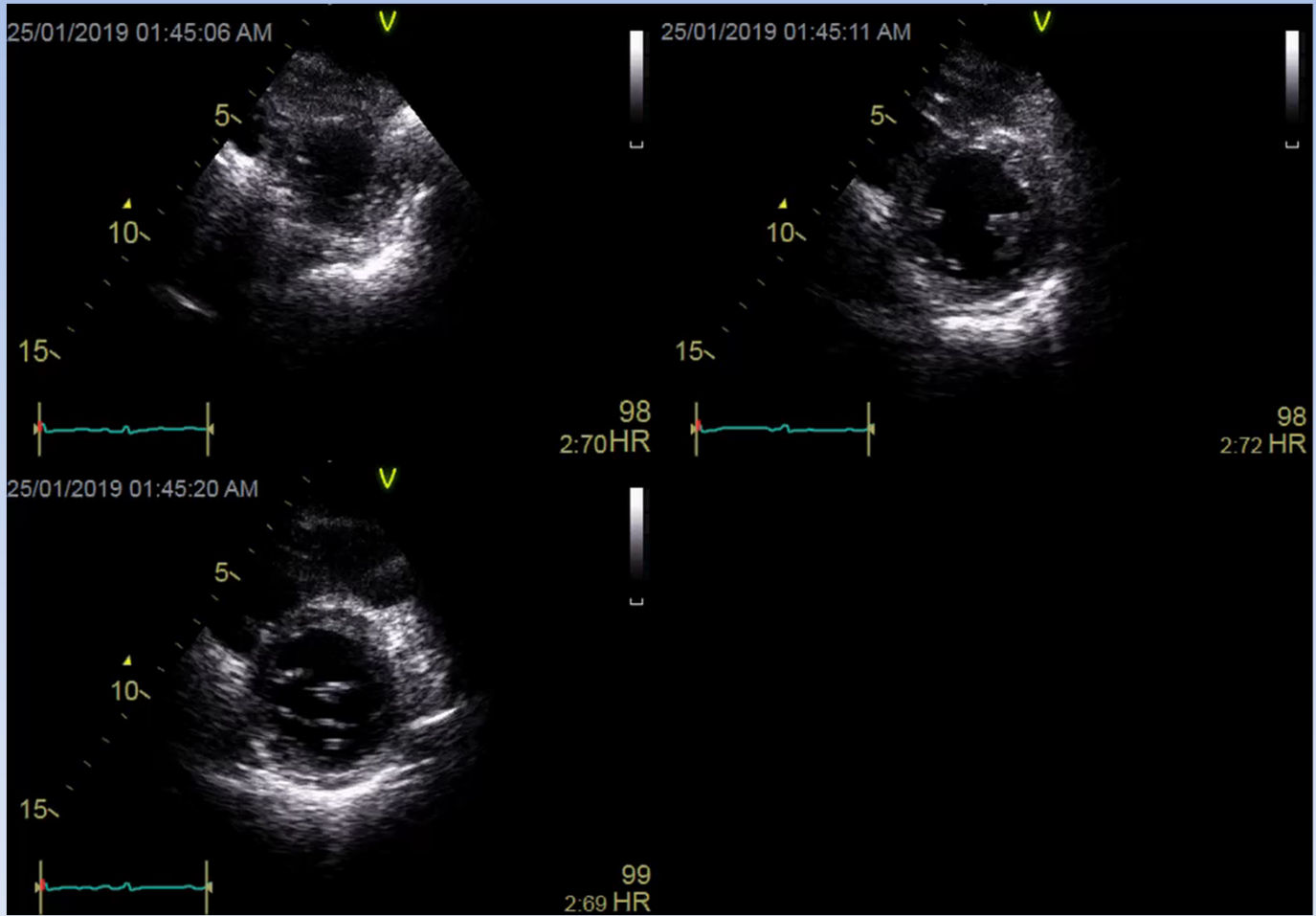
- No Disclosure

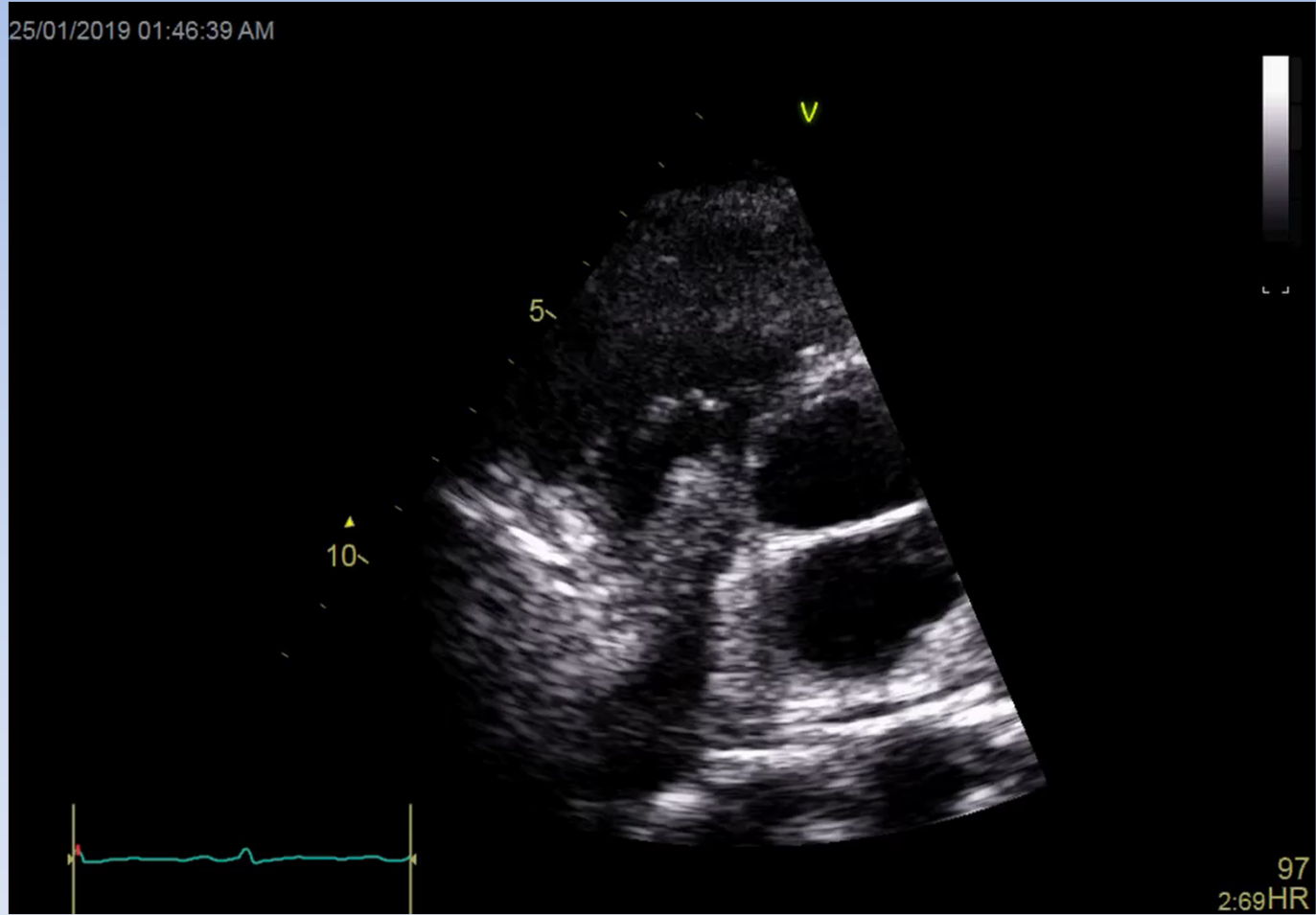
Case 1

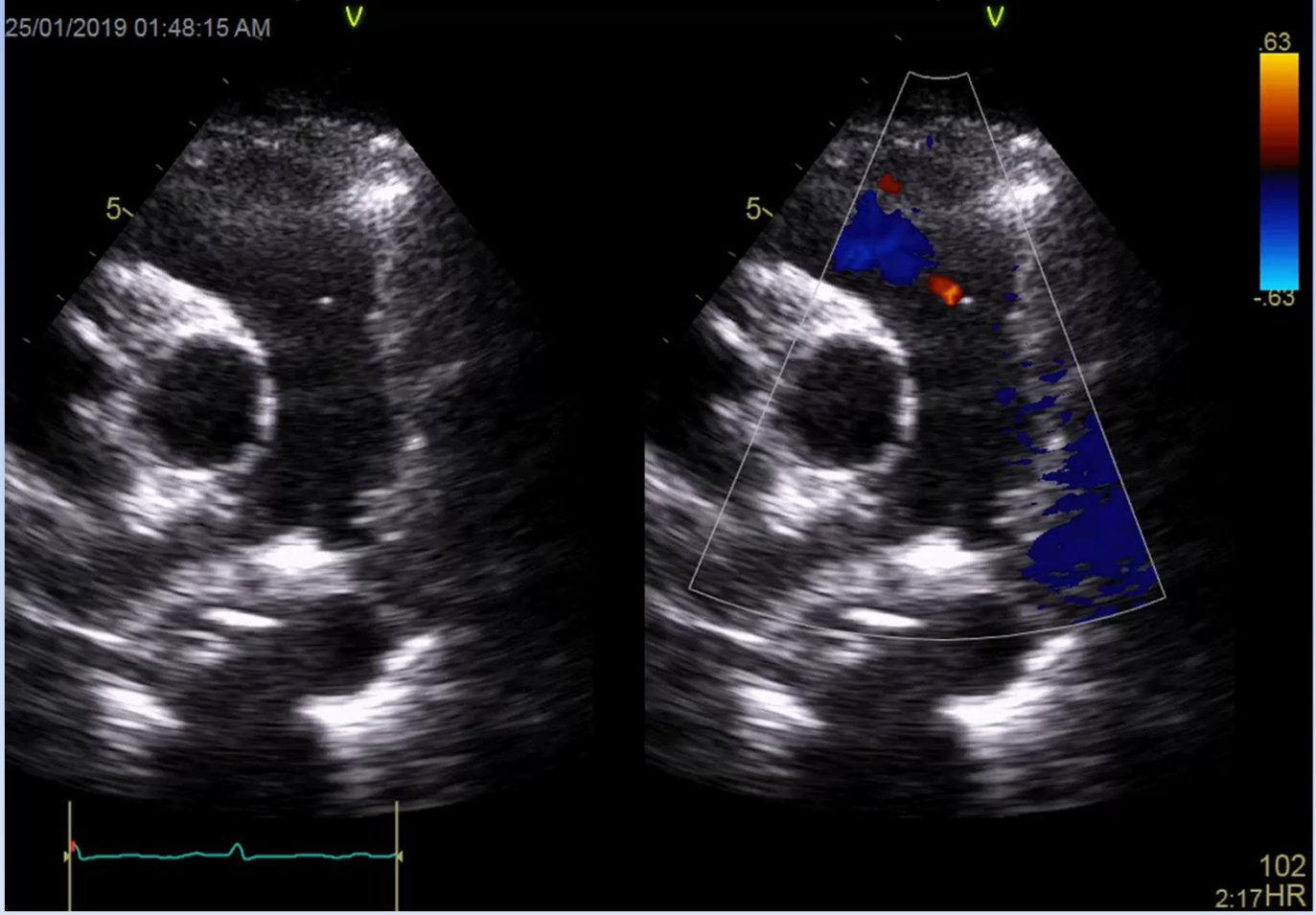
- A 33 years old lady with no past medical history of note. Presented to the ER with complain of shortness of breath for 2 days, and worsening of her left leg swelling over the last month.

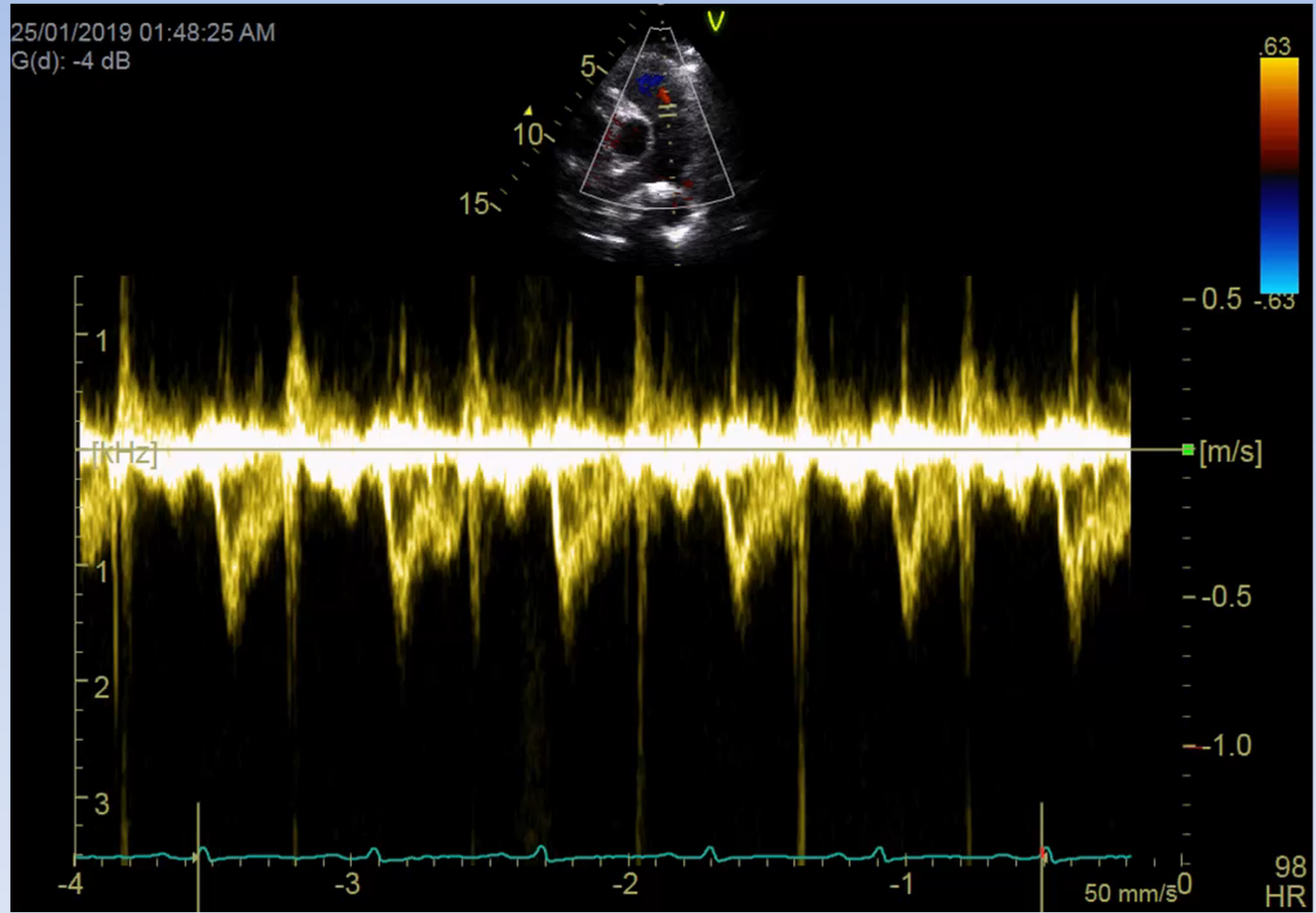


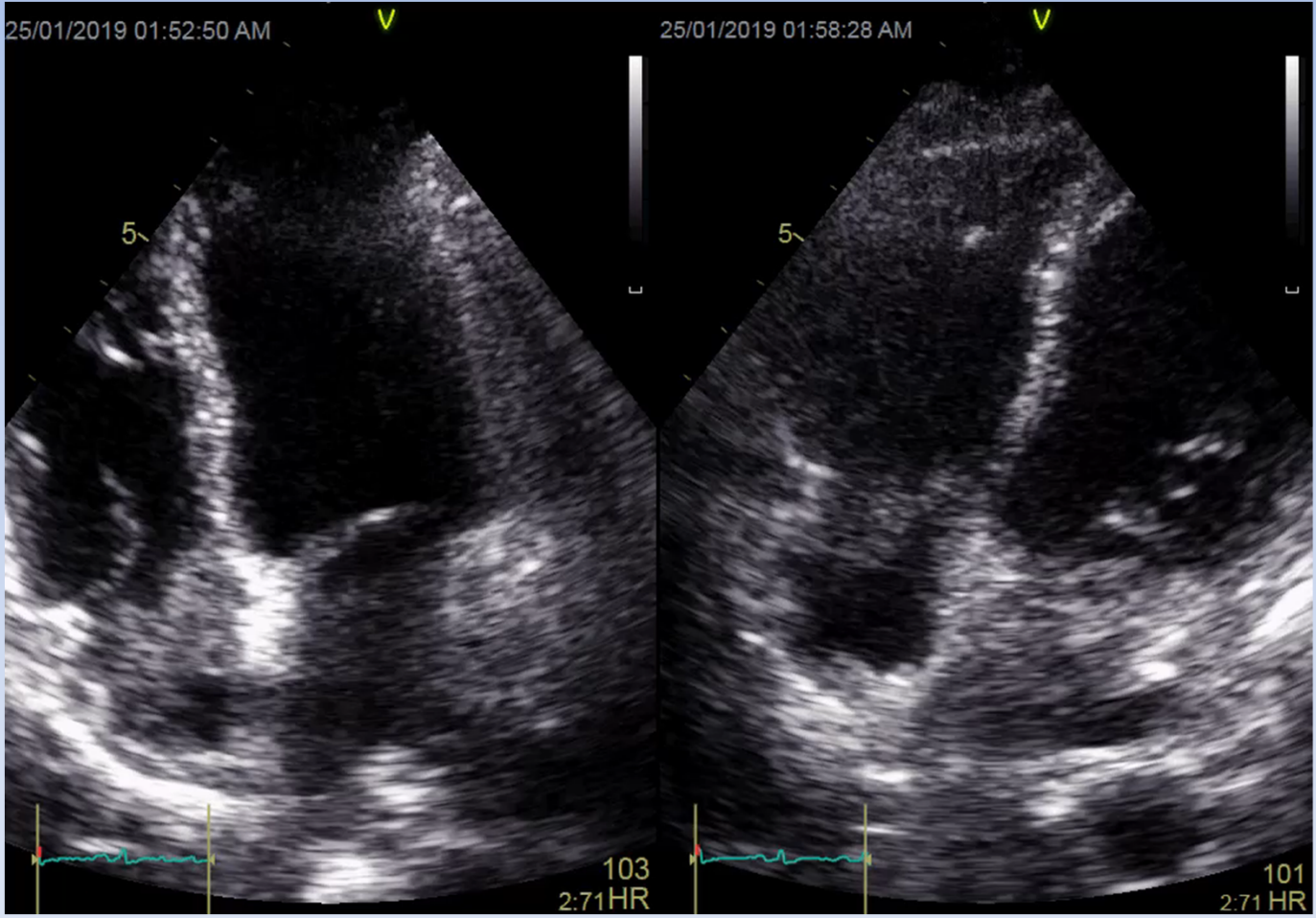


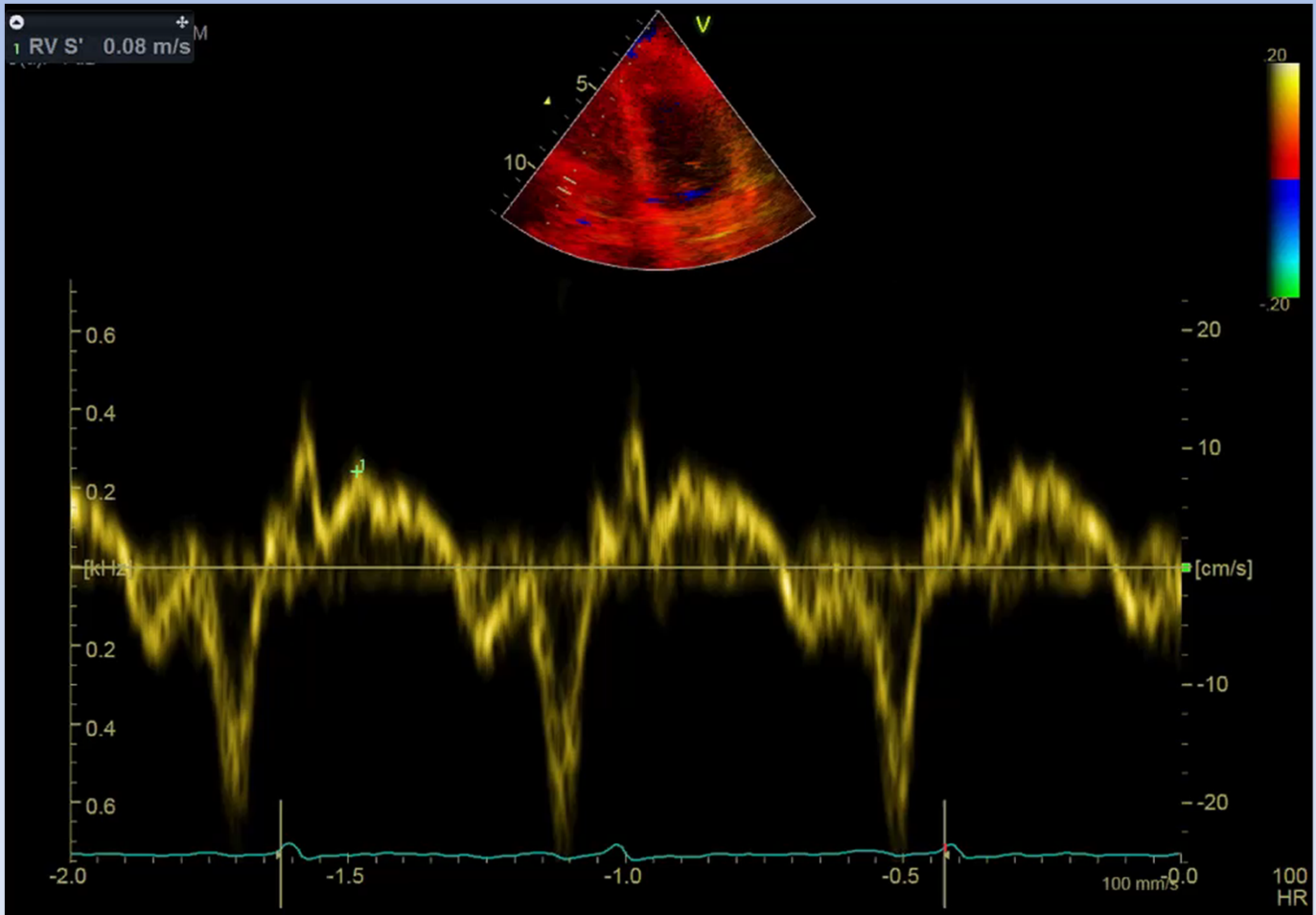


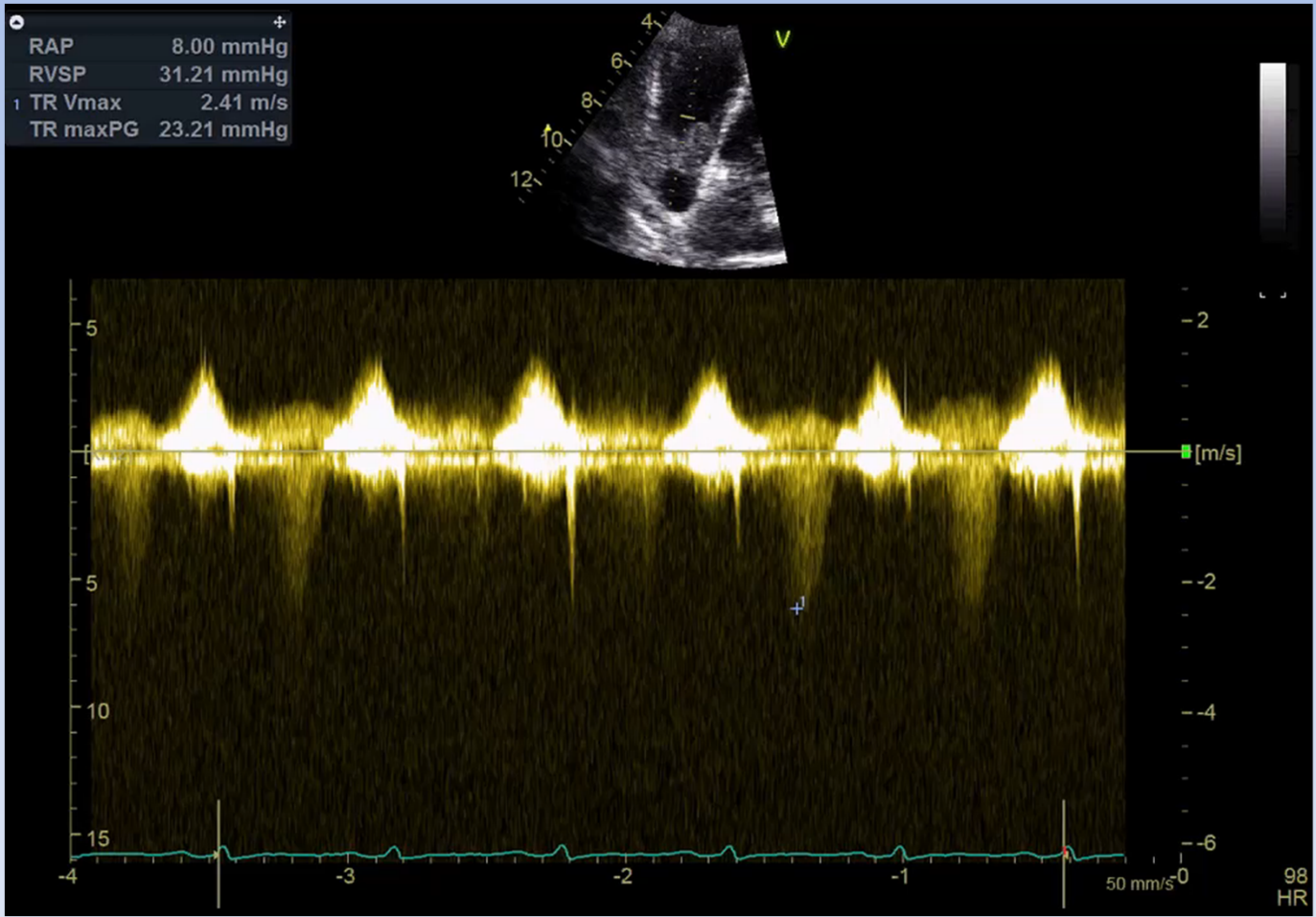




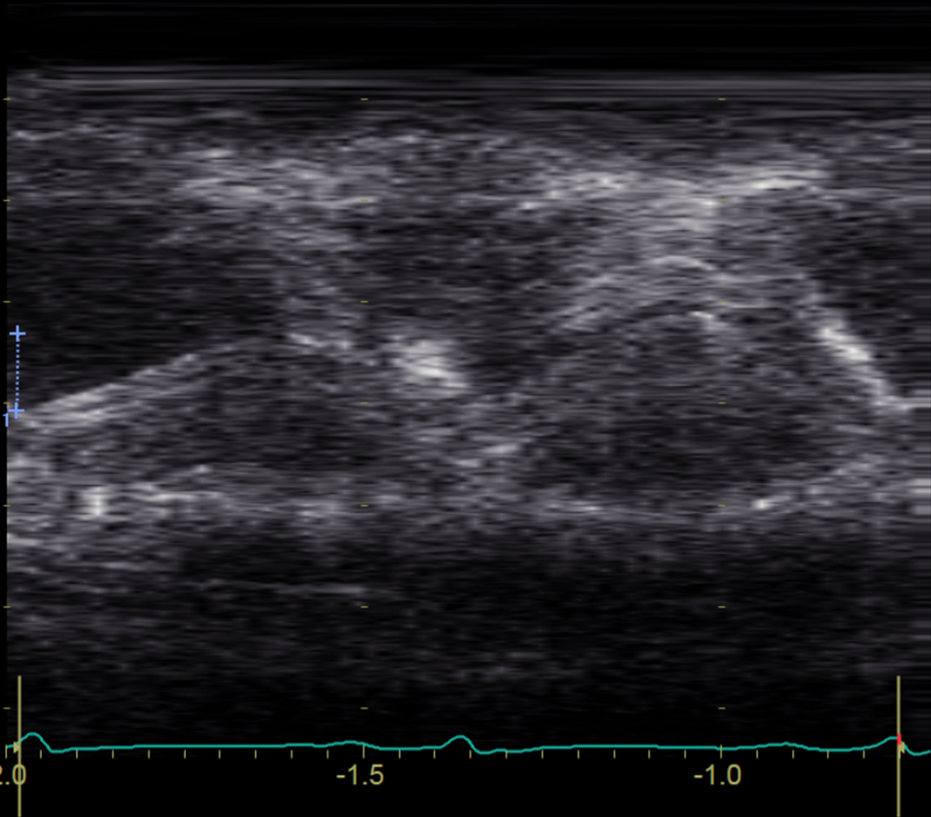
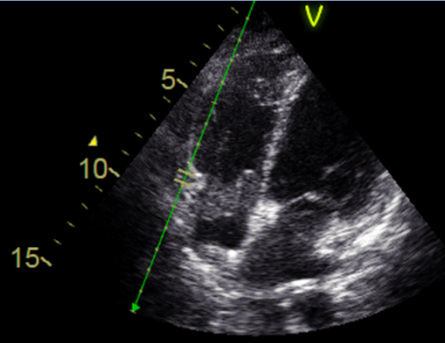








1 TAPSE 1.5 cm^M

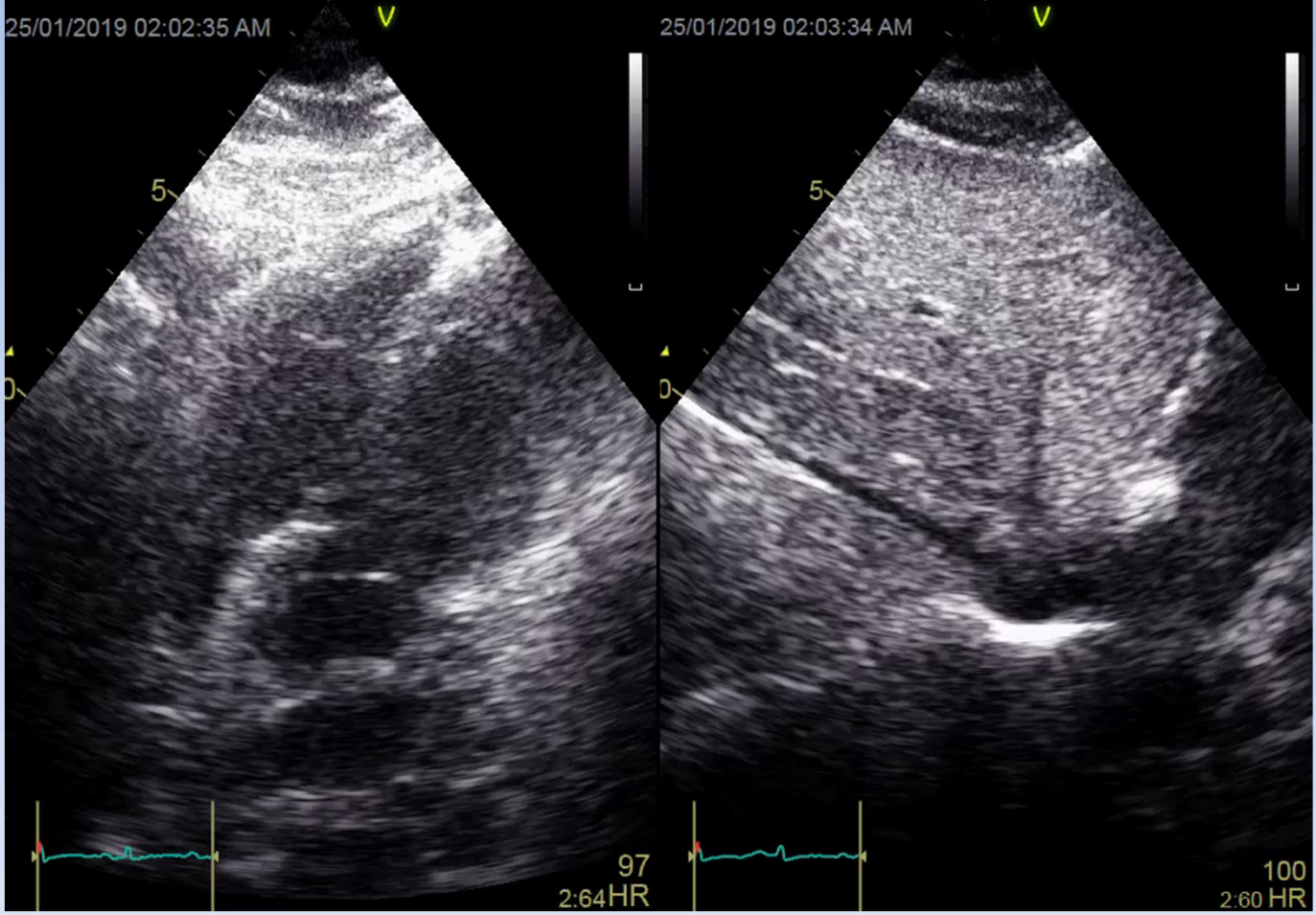


-[cm]
-2
-4
-6
-8
-10
-12
-14
0.0
100 mm/s

101 HR

95

96



*** Final Report ***

CT Angiogram pulmonary (Verified)

There is a thrombus noted involving the right and left pulmonary arteries and extending into the segmental branches. The right ventricle appears normal in size. No obvious reflux of contrast noted in the intrahepatic IVC.

There is a filling defect noted in the right atrium extending into the right ventricle-? Thrombus needs further evaluation.

There is minimal right-sided pleural effusion.

IMPRESSION:

Bilateral pulmonary thromboembolism as described above.

Filling defect noted in the right atrium and right ventricle-? Thrombus needs further evaluation

Role of Echo in Pulmonary Embolism

- In diagnosis:
 - Insensitive.
 - Nonspecific.
 - **Rapid** or **presumptive** diagnosis is required
 - Thrombus is visualized in the proximal pulmonary arteries(rare phenomenon).
 - Presence of clot in the right heart or **new** right heart strain.

Role of Echo in Pulmonary Embolism

- 30 to 40 percent of patients with PE have echocardiographic abnormalities indicative of **RV strain** or **pressure overload** including:
 - Increased RV size
 - Decreased RV function
 - Tricuspid regurgitation
 - Abnormal septal wall motion
 - McConnell's sign

Role of Echo in Pulmonary Embolism

- Prognostic purposes:
 - in patients with **confirmed** PE eg, new RV strain and RV thrombus are **poor** prognostic indicators,

- In diagnosis:
 - insensitive (since abnormalities are frequently absent in patients with PE)
 - nonspecific (since right ventricle [RV] abnormalities can be seen in other conditions including chronic pulmonary disease, pulmonary hypertension, and right ventricular infarction); in addition, the demonstration of **new** right heart strain may not be evident in the absence of a prior echocardiogram